

# CHAPTER 7

Ulcerative gastritis and  
esophagitis in two children with  
*Sarcina ventriculi* infection



Tim G.J. de Meij  
Michiel P. van Wijk  
Aad Mookhoek  
Andries E. Budding

Front Med. 2017 Aug 30;4:145

## ABSTRACT

*Sarcina ventriculi* is a gram-positive, obligate anaerobic coccus, with characteristic morphology. Only about 20 cases of infections by this micro-organism have been reported in literature, including seven in children. Affected subjects usually present with abdominal pain, nausea, vomiting and delayed gastric emptying as most prominent symptoms, but life-threatening complications like emphysematous gastritis, gastric necrosis and gastric perforation have been reported. Without exception, affected children have been described to have a concomitant gastro-intestinal related disease, such as *Helicobacter pylori* gastritis, infection with *Giardia lamblia* or *Candida* spp., or celiac disease. We report two children with *Sarcina ventriculi* infection; the first child presented with hematemesis due to ulcerative esophagitis and gastritis, without any recognized underlying gastro-intestinal disease, the second child with history of esophageal stricture had ulcerative gastritis. In both children, symptoms resolved completely following targeted antibiotics. These case descriptions highlight the high suspicion for *Sarcina ventriculi* infection needed among clinicians and pathologists in evaluating ulcerative gastritis and/or esophagitis, especially when other causes are excluded. Confirmation of *Sarcina ventriculi* infection is done by molecular microbiota detection methods, since this microorganism cannot be detected by classical culture techniques. Prompt treatment could prevent from serious complications.

## INTRODUCTION

*Sarcina ventriculi* is a gram-positive, obligate anaerobic coccus, present in the soil, with a characteristic tetrad or octet morphology. Only about 20 cases of human infections by this micro-organism have been described in literature so far, including seven in children. The majority of patients presented with abdominal pain, nausea, vomiting and delayed gastric emptying.<sup>1,2</sup> All described children had underlying gastro-intestinal diseases like *Helicobacter pylori* gastritis, infection with *Giardia lamblia* or *Candida* spp., or celiac disease.<sup>2-7</sup> In some cases, infection was associated with life-threatening complications, like emphysematous gastritis and gastric perforation.<sup>3,6</sup> We present two children with *Sarcina ventriculi* infection, one of them without an underlying gastro-intestinal disease, who responded well on targeted antibiotics.

## CASE PRESENTATIONS

### Case 1

The patient is a 12-year old girl from Turkish origin with a history of psychomotor retardation, refractory epilepsy based on West syndrome, and percutaneous endoscopic gastrostomy (PEG) for administration of long-term enteral nutrition. She previously suffered from two *Helicobacter pylori* associated gastritis episodes, successfully eradicated with triple therapy. She was on phenobarbital and gabapentin and in addition she used omeprazole (20 mg/day) for persistent GERD symptoms with negative stool antigen tests for *Helicobacter Pylori*. She was admitted to the hospital because of mild dehydration due to intractable vomiting since three days, including hematemesis on the last day. Aspiration of stomach fluid via PEG tube revealed retention of large amount of brownish fluid. On physical examination she was tachycardic (110/min), with normal blood pressure and oxygen saturation. Palpation of the abdomen was not painful, and no other physical signs, next to her pre-existent neurologic impairment, were present. Laboratory investigation showed normal haemoglobin concentration (9.5 mmol/l), mean cellular volume 94 fl, normal platelet count and normal infection and clotting parameters. Differential diagnosis included Mallory-Weiss syndrome, viral gastro-enteritis, esophagitis, recurrence of *Helicobacter pylori* associated ulcer/gastritis and bleeding from esophageal varices. On abdominal ultrasound no signs of portal hypertension were found. *Helicobacter pylori* antigen stool test was negative. Omeprazole was increased to 40 mg/day, no hematemesis or other alarm symptoms were observed

during admission and esophagogastroduodenoscopy was therefore not performed. Patient was discharged in good clinical condition after three days of enteral rehydration. One month later, patient was readmitted in an epileptic status, possibly due to insufficient intake of antiepileptic medication linked to a gradual increase of vomiting over the last few weeks. Several days prior to presentation, mother had aspirated large amounts of bloody retention from the stomach, yet haemoglobin level was not decreased compared to the previous admission. Convulsions were adequately treated with midazolam. One day after admission patient had an episode of hematemesis and an esophagogastroduodenoscopy was performed under general anesthesia after 8 hours of fasting. Endoscopy showed a severe erosive esophagitis of the distal 15 cm of the esophagus (Figure 7.1). Furthermore, a multifocal hemorrhagic corporal and antral gastritis with two antral circular ulcers with a diameter of 5 mm was observed (Figure 7.2). Notably, patient had a large amount of stomach retention, indicative of delayed gastric emptying. Histological examination of esophageal biopsies showed severe ulcerative esophagitis with presence of microorganisms in the necrotic debris overlying the ulcer base. These microorganisms appeared to be arranged in tetrad (Figure 7.3A), but on higher magnification were shown to be arranged in cubes

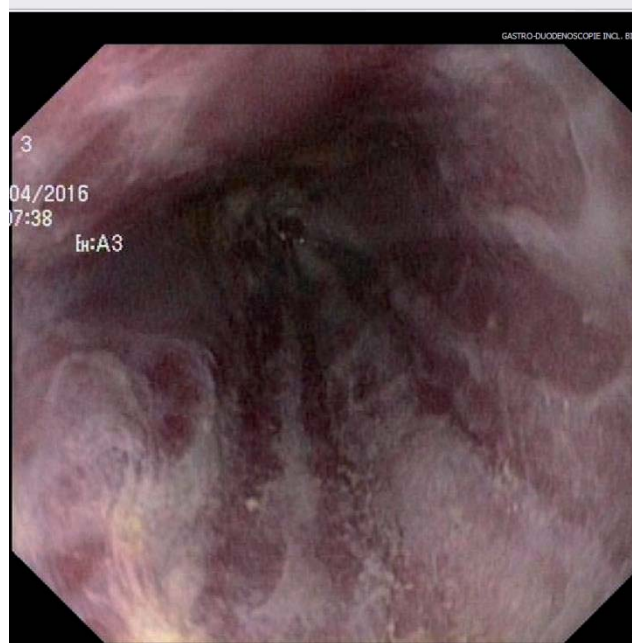
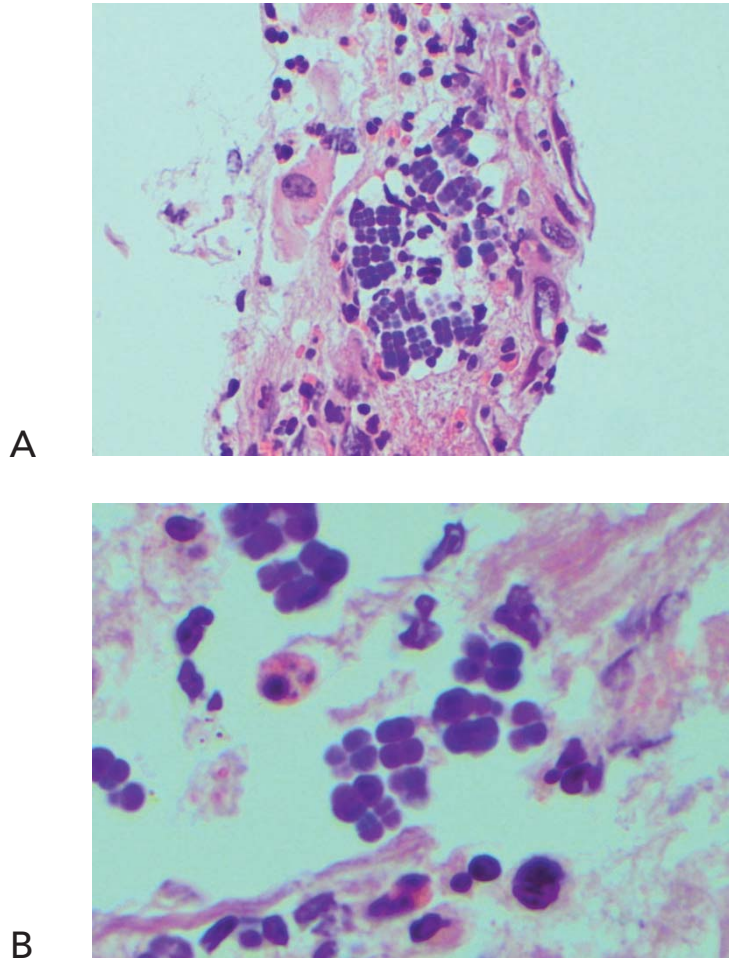


Figure 7.1 Erosive esophagitis.

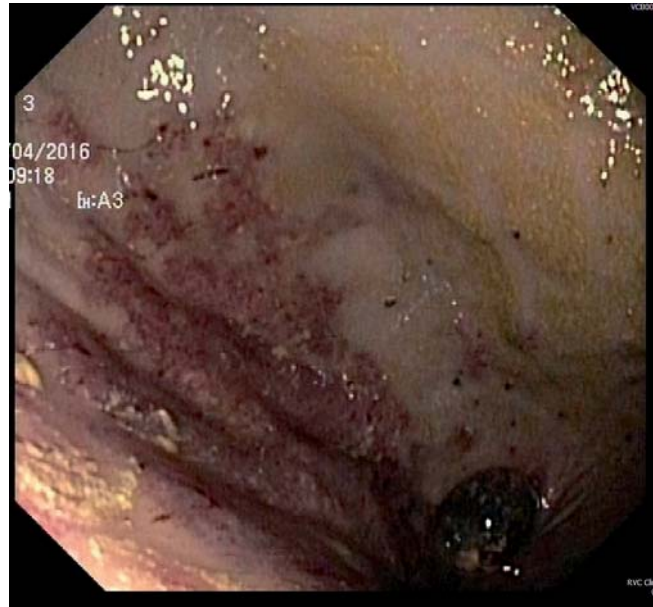

Figure 7.2 Erosive gastritis.

composed of eight individual spheres (Figure 7.3B). This morphology is characteristic of *Sarcina ventriculi*. Gastric and duodenal biopsies also showed *Sarcina ventriculi* on the surface epithelium. *Helicobacter pylori* and *Giardia lamblia* were not observed and there were no signs of celiac disease. Culture of the biopsies was negative, including that for *Helicobacter pylori*. We applied a eubacterial molecular detection technique, called IS-pro, which confirmed the presence of *Sarcina ventriculi*. Patient was treated with ciprofloxacin and metronidazole for ten days and symptoms of bloody stomach retention and hematemesis resolved completely within several days. Control esophagogastroduodenoscopy performed after six weeks showed complete healing of the gastric and esophageal mucosa. In the mucosal biopsies, *Sarcina ventriculi* could no longer be detected. Duration of follow-up was nine months, no recurrence of symptoms has been reported in this period.



**Figure 7.3** *Sarcina ventriculi* in esophageal biopsies. These microorganisms appear to be arranged in tetrad (Figure 7.3A, 200x), but on higher magnification appear to be arranged in cubes composed of eight individual spheres (Figure 7.3B, 400x).

## Case 2

The patient is a 15-year old, Caucasian girl with history of severe neurological impairment and epilepsy due to hemorrhage from a cerebral arteriovenous malformation at age of eight years. She was prescribed Clobazam and Keppra as anti-epileptic agents and had a PEG tube to administer enteral nutrition. She presented with respiratory failure due to aspiration pneumonia for which mechanical ventilation was required. Because of the inability

to insert a nasogastric tube, a single-contrast study of the esophagus was performed at the day after admission, which showed a 10 cm long mid-esophageal stricture. An upper endoscopy was performed which confirmed the presence of a midesophageal pinpoint stenosis. Endoscopy was also performed through the gastrocutaneous fistula for retrograde inspection of the distal esophagus. We observed a diffuse erosive gastritis and a large gastric circular ulcer with a diameter of 10 mm at the gastro-esophageal junction, no signs of esophagitis. Furthermore, a significant amount of stomach retention was seen, despite 12 hours of fasting, suggestive of delayed gastric emptying. Histological examination of gastric biopsies showed active gastritis with the presence of microorganisms arranged in tetrad, characteristic of *Sarcina ventriculi*, which was confirmed by IS-pro technique. *Helicobacter pylori* and *Giardia lamblia* were not detected. Patient was prescribed ciprofloxacin and metronidazole for ten days, next to omeprazole (40 mg/day). At endoscopic follow-up six weeks following antibiotics, the gastritis and gastric ulcer were healed completely and *Sarcina ventriculi* could no longer be detected from the biopsies. Endoscopic dilatation of the esophageal stricture was successfully performed using Savary-Gilliard bougies.

## DISCUSSION

In 1842, John Goodsir was the first to describe the presence of *Sarcina* micro-organisms in the stomach of a patient presenting with abdominal pain, bloating and vomiting.<sup>8</sup> The pathogenic role of *Sarcina ventriculi* has been well established in the veterinary literature, including description of several fatal cases, called 'abomasal bloat', in livestock.<sup>3,9</sup> The potential pathogenicity of *Sarcina* organisms in humans has been questioned until recent years, since only few infections in humans have been described. *Sarcina ventriculi* has been detected in asymptomatic subjects,<sup>10,11</sup> but can also cause severe infections with life-threatening complications. Patients with *Sarcina ventriculi* commonly present with abdominal pain, nausea, vomiting, and as in our case, delayed gastric emptying.<sup>1,2</sup> In fact, it has been suggested that impaired stomach emptying could be a risk factor for the growth of *Sarcina ventriculi*,<sup>12,13</sup> since development of this microbe is impossible in the absence of carbohydrates. Involved site of infections include the stomach (85%), esophagus (10%) and duodenum (5%).<sup>1</sup> The majority of affected patients do not have mucosal injury on endoscopy, but increasing evidence suggests that *Sarcina ventriculi* is associated with gastric ulcers in over 30% of cases, with a subsequent risk of complications like emphysematous gastritis and gastric perforation.<sup>1,2</sup> Only seven children with symptomatic *Sarcina ventriculi*

infection have been described in literature so far;<sup>2-7</sup> two of them presenting with (partial) gastric necrosis. Notably, all described children had a comorbid gastrointestinal disease, including *Helicobacter pylori* gastritis (n=2), infection with *Giardia lamblia* or *Candida spp.*, history of esophageal atresia with post gastric pull through with anastomotic narrowing, and celiac disease. Our pediatric case (cae 1) is the first symptomatic *Sarcina ventriculi* infection without another (recognized) gastrointestinal diagnosis. In three of seven affected children, endoscopy revealed the presence of distal esophagitis, none of them had hematemesis as presenting symptom.<sup>2,13</sup> Cultivation of *Sarcina ventriculi* is complicated by its complex nutritional requirements, but diagnosis can usually be made based on the typical morphologic features.<sup>5</sup> Diagnosis can be confirmed by means of molecular techniques like sequencing or, as in our cases, by IS-pro.<sup>14</sup> Treatment of *Sarcina ventriculi* usually consists of proton pump inhibitors and antibiotics, with metronidazole and ciprofloxacin as most frequently prescribed agents.<sup>10</sup> In our first case description, patient was already on proton pump inhibitors prior to onset of complaints and recovered both clinically and endoscopically following a course of ciprofloxacin and metronidazole.

The association between *Sarcina ventriculi* infections and esophageal strictures, like in case 2, has already been described over a century ago.<sup>15</sup> In an intriguing experiment by Beijerinck et al, performed in 1911 under strict anaerobic conditions to prove the similarity between *Sarcina ventriculi* isolated from garden soil and from stomach contents, the researchers used material from patients with esophageal stenosis and suffering from *Sarcina ventriculi* infection.<sup>15</sup> Interestingly, this association has not been described in subsequent reports on human *Sarcina ventriculi* infections. In our case 2, *Sarcina ventriculi* was detected in mucosal biopsies from the stomach but, notably, not from the esophagus. We therefore believe that *Sarcina ventriculi* infection is more likely a consequence rather than a cause of esophageal strictures; severe stenosis may create optimal anaerobic conditions for *Sarcina ventriculi* to grow.

In conclusion, *Sarcina ventriculi* is a rare cause of gastritis and/or esophagitis in children, with delayed gastric emptying as possible etiologic factor. Infection in children often occurs in the presence of comorbid gastro-intestinal diseases, however we have shown for the first time that it can occur in children without underlying gastrointestinal diseases. Because *Sarcina ventriculi* infection may lead to life-threatening complications it should be treated promptly with antibiotics and a proton pump inhibitor.



## REFERENCES

1. Gaspar BL. The significance of *Sarcina* in routine surgical pathology practice. *APMIS*. 2016 Jun; 124(6):436-43.
2. Lam-Himlin D, Tsiatis AC, Montgomery E, et al. *Sarcina* organisms in the gastrointestinal tract: a clinicopathologic and molecular study. *Am J Surg Pathol*. 2011 Nov;35(11):1700-5.
3. Laass MW, Pargac N, Fischer R, et al. Emphysematous gastritis caused by *Sarcina ventriculi*. *Gastrointest Endosc*. 2010;72:1101-3.
4. Karakus E, Kirsaclioglu CT. Coincidence of celiac disease with *Sarcina* infection. *Turk J Gastroenterol* 2014;25(Suppl 1):318.
5. Kumar M, Bhagat P, Bal A, et al. Co-infection of *Sarcina* and *Giardia* in a child. *Oxf Med Case Reports* 2014;2014:118-9.
6. Tolentino LF, Kallichanda N, Javier B, et al. A case report of gastric perforation and peritonitis associated with opportunistic infection by *Sarcina ventriculi*. *Lab Med* 2003;34:535-7.
7. Canale-Parola E, Wolfe R. Studies on *Sarcina ventriculi*. I. Stock culture method. *J Bacteriol*. 1960 Jun;79:857-9.
8. Goodsir J. History of a case in which a fluid periodically ejected from the stomach contained vegetable organisms of an undescribed form. *Edinburgh Medical and Surgical Journal*. 1842;57: 430-43.
9. Edwards GT, Woodger NG, Barlow AM, et al. *Sarcina*-like bacteria associated with bloat in young lambs and calves. *Vet Rec* 2008;163:391-3.
10. Haroon Al Rasheed MR, Kim GJ, et al. A Rare Case of *Sarcina ventriculi* of the Stomach in an Asymptomatic Patient. *Int J Surg Pathol*. 2016 Apr;24(2):142-5.
11. Ferrier D. The Constant Occurrence of *Sarcina Ventriculi* (Goodsir) in the blood of Man and the Lower Animals: With Remarks on the Nature of Sarcinous vomiting. *Br Med J*. 1872 Jan 27;1(578): 98-9.
12. Ratuapli SK, Lam-Himlin DM, Heigh RI. *Sarcina ventriculi* of the stomach: a case report. *World J Gastroenterol*. 2013;19(14):2282-5.
13. Sauter JL, Nayar SK, Anders PD, D'Amico M, Butnor KJ, Wilcox RL. Co-existence of *Sarcina* Organisms and *Helicobacter pylori* Gastritis/Duodenitis in Pediatric Siblings. *J Clin Anat Pathol (JCAP)* 2013;1:391-3.
14. Budding AE, Grasman ME, Lin F, et al. IS-pro: high-throughput molecular fingerprinting of the intestinal microbiota. *FASEB J* 2010;24:4556-64.
15. Beijerinck MW. An experiment with *Sarcina ventriculi*. In: Huygens Institute - Royal Netherlands Academy of Arts and Sciences (KNAW), Proceedings, 13 II, 1910-1911, Amsterdam, 1911;1237-40.

